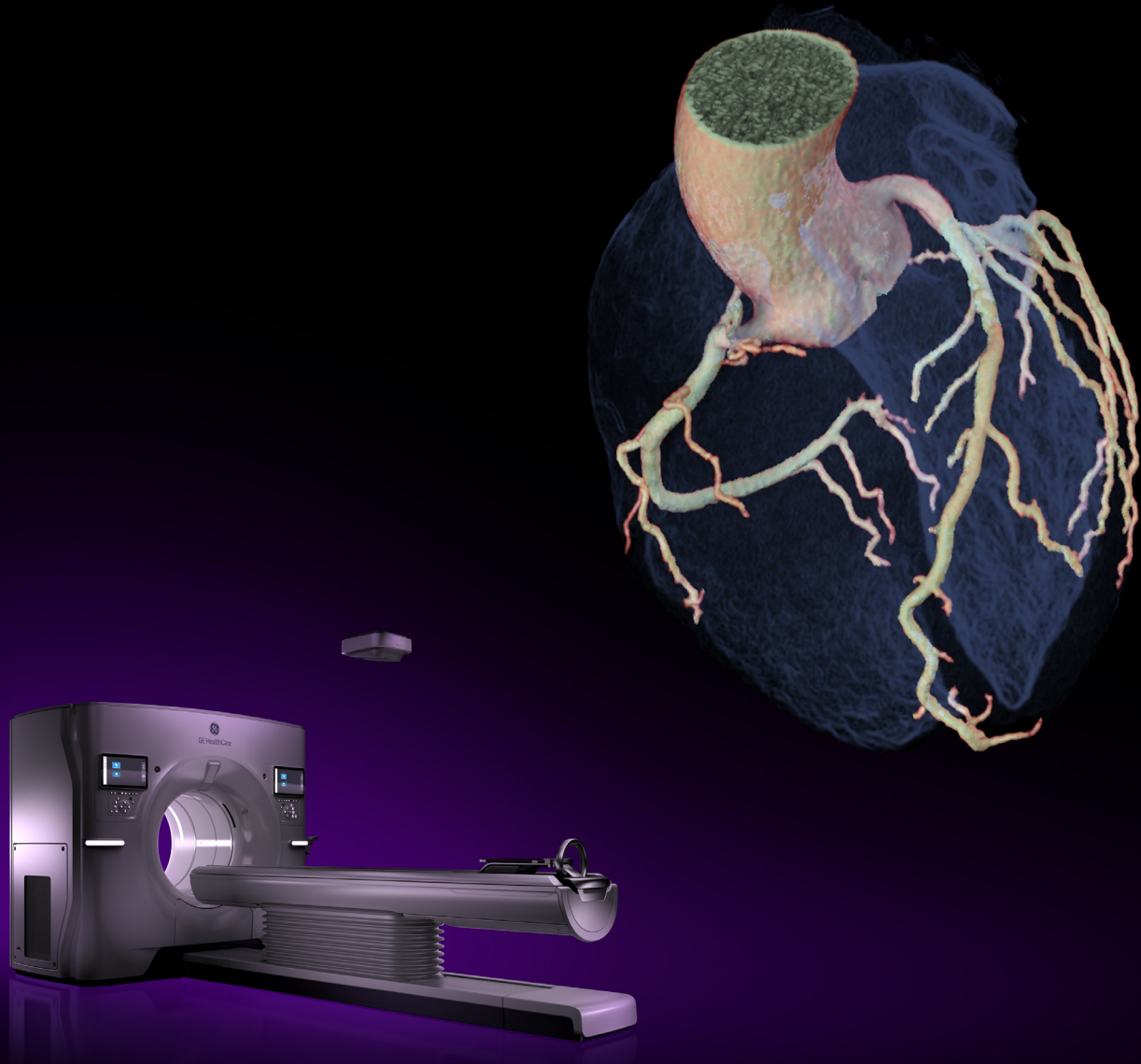




GE HealthCare



Unlimited 1-Beat Cardiac

A Summary of Peer-Reviewed Clinical Evidence

Authors: Hugo Pasquier, Ph.D; Darin Okerlund, MSc; Renee Yao, BEc, MBA

Content

Introduction	3
Unlimited 1-Beat Cardiac for Every Patient, Every Exam.....	4
Unlimited 1-Beat Cardiac Technology Enablers.....	6
Improve CCTA Diagnostic Performance in Patients with Very High Heart Rate (>80bpm)	9
Improve CCTA Diagnostic Performance in Patients with Atrial Fibrillation.....	11
Explore Free-Breathing CCTA without Heart Rate Control	13
Explore CCTA without Heart Rate Control.....	14
CCTA at Low Dose of Radiation and Contrast Injection	15
Submillisievert CCTA in Children with Coronary Artery Anomalies	17
Improve Diagnostic Performance in Patients with Functionally Significant CAD.....	19
Improve Diagnostic Performance in Patients with Suspected In-Stent Restenosis or CAD Progression	20
Replace Invasive Coronary Angiography in Treatment Planning for Patient with Multivessel Disease	22
One-Stop TAVI/TAVR Protocol with Only One Contrast Medium Injection	23
Unleash the Full Potential with ECG-less Cardiac	25
References.....	26

Introduction

Since its emergence in the late 1990s, cardiac computed tomography (CT) has undergone rapid technological advancements and has become a robust non-invasive imaging tool for the diagnosis, prognosis and treatment planning of heart disease.

Based on strong research and clinical evidence, guideline bodies have endorsed incorporating cardiac CT more definitively than before. The 2019 European Society of Cardiology guidelines for chronic coronary syndromes recommend cardiac CT as the initial test to diagnose obstructive coronary artery disease (CAD) in symptomatic patients¹. The joint 2022 American Heart Association and American College of Cardiology guidelines for chest pain management strongly recommend using cardiac CT in the evaluation and diagnosis of both stable and acute chest pain².

GE HealthCare (GEHC) has been the industry leader in pioneering cardiac CT technologies since 1998's introduction of 4-row multi-slice CT that made cardiac CT a technical reality. Since then, key technology advancements have been introduced to transform cardiac CT from a technical novelty to an easy-to-use, routine clinical tool (Figure 1).

The most important breakthrough was the introduction of whole-heart-coverage CT systems (Revolution™ CT in 2013, Revolution Apex CT in 2018 and Revolution Apex Elite in 2021) that combine the benefits of whole-heart-coverage, fast temporal resolution and high spatial resolution in one robust cardiac CT solution: Unlimited 1-Beat Cardiac.

As the name suggests, Unlimited 1-Beat Cardiac is a wing-to-wing CT acquisition and reconstruction solution that obtains high-quality coronary CT angiography (CCTA) and structural heart exams within a single cardiac cycle in patients with any heart rate and rhythm.

By capturing the necessary data in a single heartbeat, the overall imaging time is decreased with Unlimited 1-Beat Cardiac. It may improve diagnostic performance of CCTA for challenging patients in the presence of an elevated heart rate (HR), HR variability and arrhythmia, and difficulty following breath-hold commands. It streamlines the cardiac CT workflow by eliminating the need to administer beta-blockers. It also creates one-stop cardiac protocols to allow coronary evaluation in exams indicated for structural heart disease, congenital heart diseases and myocardial evaluation.

Worldwide users and researchers have conducted multiple studies to evaluate its diagnostic performance in imaging challenging cardiac patients. This white paper summarizes the evidence from key studies to provide references for practitioners incorporating this technology into their clinical practice³.

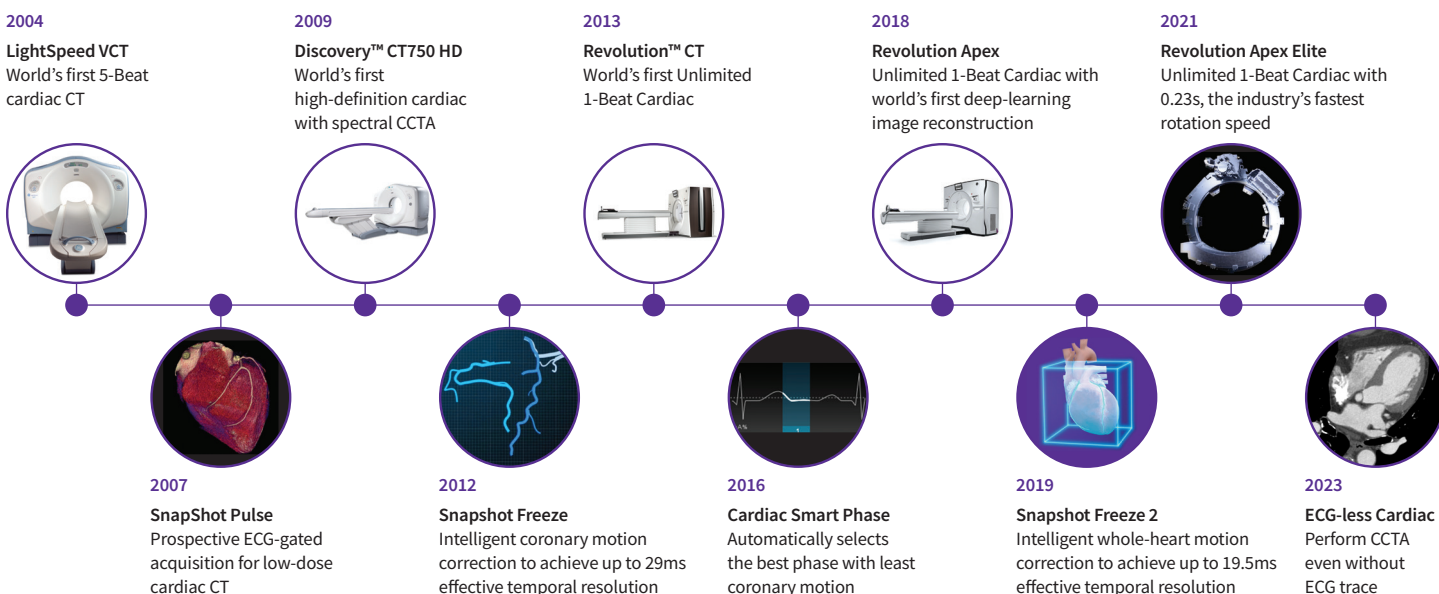


Figure 1. GE HealthCare innovation timeline in cardiac CT.

³ The studies varied by clinical indications, study protocols and comparison methods. The results and conclusions obtained in these studies are applicable to the specific studies cited and may not be generalizable or reproducible in every practice.

Unlimited 1-Beat Cardiac for Every Patient, Every Exam

While other cardiac CT systems may provide a 1-beat cardiac feature that can be applied only to patients with low and stable heart rates (<60bpm), Unlimited 1-Beat Cardiac can apply to all heart rates and rhythms, even in challenging patients with very high heart rates (>80bpm) and atrial fibrillation (AF).

Table 1 summarizes key findings of Unlimited 1-beat Cardiac studies from selected peer-reviewed publications.

Subjects	Key findings	Population	Reference
CCTA in high heart rate patients	Allows high CCTA diagnostic accuracy for the detection of >50% coronary stenosis, with markedly low radiation exposure in high heart rate patients (2.9mSv in heart rate ≥80bpm) by acquiring data within the phase between end-systole and end-diastole in one cardiac cycle.	100 adult patients with HR ≥80bpm and 102 with HR ≤65bpm, all with a clinical indication for CCTA because of suspected but unknown CAD	3
CCTA in atrial fibrillation patients	High diagnostic accuracy of CCTA in patients with atrial fibrillation, compared to the gold standard of ICA, at a markedly lower effective dose.	83 adult patients with atrial fibrillation and 83 with sinus rhythm, all without known CAD scheduled for clinically indicated elective ICA	22
Free-beathing CCTA	The free-breathing CCTA with unlimited 1-Beat Cardiac protocol enabled coronary evaluation with excellent image quality, and remarkable diagnostic accuracy despite high heart rate during the acquisition.	325 free-beathing adult patients and 291 breath-holding, all with chest pain referred for CCTA for ruling out CAD	27
CCTA without heart rate control	With Unlimited 1-Beat Cardiac CT and experienced radiographers (technologist), drugless radiographer-led CCTA can deliver a 20-minute CCTA timeslot for cardiac patients with satisfactory image quality, while allowing reallocation of medical practitioner time to CCTA reporting.	1028 stable adult patients with chest pain referred for CCTA	28
CCTA with low dose of radiation and contrast use	Unlimited 1-Beat Cardiac with low kV and TrueFidelity is reported to demonstrate up to 54.5% radiation dose reduction and 50.6% iodine contrast medium usage reduction in normal size patients, and up to 45% radiation dose reduction and 43% iodine contrast medium usage reduction in overweight patients.	50 adult patients in a low-dose group and 50 in a conventional protocol group, all with BMI ≥ 26kg/m ² suspected of CAD and referred to CCTA	6 7
CCTA in pediatric patients	For the first time in a pediatric population, the COROPEDIA clinical trial demonstrated Unlimited 1-Beat CCTA for pediatric patients with coronary artery anomalies, with submillisievert radiation dose.	50 pediatric patients with congenital heart disease and with a suspected or confirmed coronary artery anomaly	34
FFRct and CT Perfusion	A sequential strategy based on Unlimited 1-Beat CCTA followed by FFRct and myocardial perfusion imaging has the ability to provide a full overview of anatomical and functional aspects of CAD.	85 symptomatic CAD adult patients with intermediate and high-risks	37

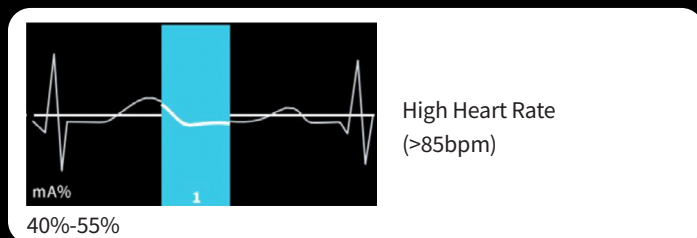
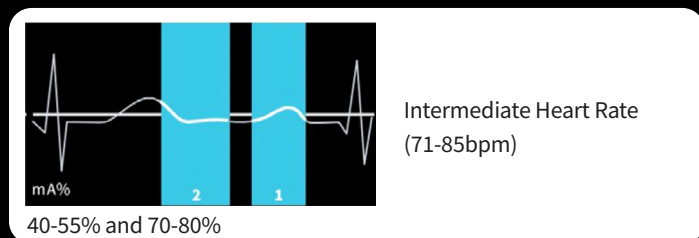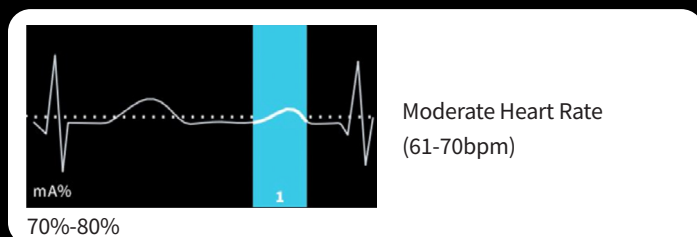
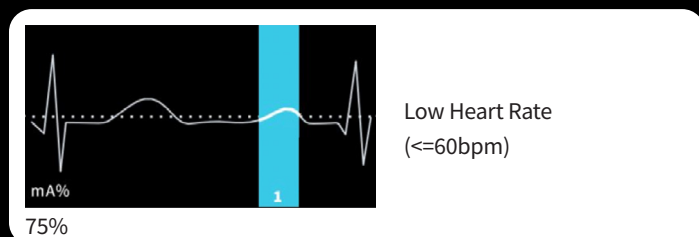
Subjects	Key findings	Population	Reference
In-stent stenosis	For patients with coronary stents, Unlimited 1-Beat Cardiac with high-resolution mode and TrueFidelity can improve the clarity and visibility of the in-stent lumen; concordant with myocardial CTP can significantly improve overall diagnostic performance while maintaining relatively low radiation dose.	47 adult patients with coronary stenting and suspected CAD progression, 150 stented adult patients with suspected in-stent restenosis or CAD progression	39 40
CT for CABG planning	CABG guided by Unlimited 1-Beat CCTA is feasible and has an acceptable safety profile in a selected population of complex CAD.	114 adult patients with equivalent angina, silent ischemia, and chronic or stabilized acute coronary syndrome for surgical revascularization	43
TAVI planning	TAVI protocols allow the holistic assessment of aortic root, coronary arteries and peripheral vessels in the same exam with low iodine contrast medium use and low radiation dose, potentially leading to a reduction of unnecessary ICA in patients without CAD, as well as the total cost for patients' management.	115 adult patients referred for CT and ICA before TAVI planning due to severe symptomatic aortic valve stenosis and considered at high surgical risk	45

Unlimited 1-Beat Cardiac Technology Enablers

Unlimited 1-Beat Cardiac offers a group of versatile scan protocols that enable 1-beat prospectively electrocardiogram (ECG) gated acquisition at different cardiac phases and heart rates, within a single heartbeat, as Figure 2 illustrates. This capability is made possible by a comprehensive and robust end-to-end CT system design, including hardware, firmware and software (figure 3).

1-Beat Protocol

1-Beat CCTA protocol



1-Beat CCTA and Function protocol

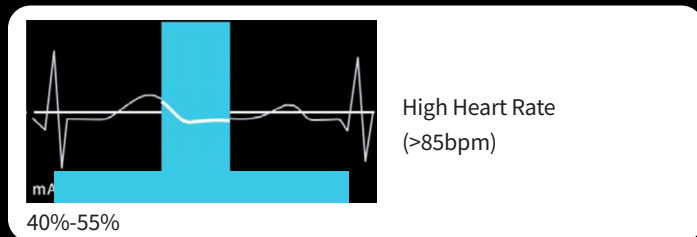
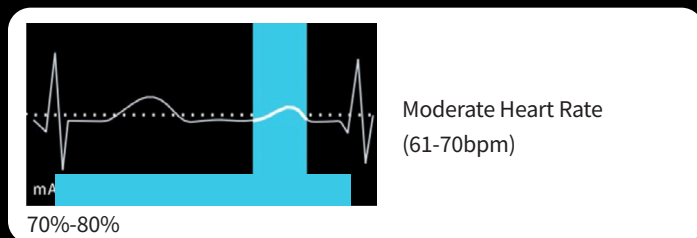
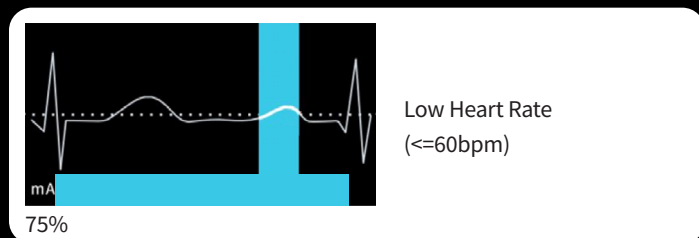


Figure 2: Examples of GEHC Unlimited 1-Beat Cardiac reference protocols.

The out-of-the-box reference protocols provide baseline 1-beat acquisition and reconstruction windows as a function of heart rates and rhythm. Users can modify and create tailor-made 1-beat protocols based on the clinical indications, requirement for image quality and radiation dose. The additional standard Auto Gating profiles are available for other cardiovascular clinical use cases.

160mm Whole-Heart-Coverage Clarity Detector

The 160mm Clarity Detector's z-coverage makes whole-heart coverage in a single axial rotation a reality. This hardware breakthrough eliminates the step-stair artifact, which is reported to occur in up to 18% of patients⁴ and 77% of coronary segments in different CT scanners with narrow detectors⁵.

The Clarity Detector also supports high-definition (HD) imaging mode with a 8,914Hz sampling rate. HD imaging mode delivers the highest 0.23mm spatial resolution, which helps facilitate accurate stenosis assessment, in-stent investigation and calcium de-blooming.


1300 mA Quantix X-Ray Tube

The Quantix X-ray tube combines 1300mA output and 160mm z-coverage in a single axial exposure. The maximum 1,300mA output not only ensures enough X-ray photon flux for high-quality CCTA in obese patients, it also makes scanning at low kV (70, 80kV) a routine CCTA protocol. Low kV scans potentially enhance the image contrast to better delineate the coronary arteries, and potentially reduce radiation dose and optimize the amount of contrast medium needed for the scan, which can be beneficial for patients with renal insufficiency or other contraindications to contrast media^{6,7}.


19.5msec Effective Temporal Resolutionⁱ with Intelligent Motion Correction

Temporal resolution is a critical factor in cardiac CT imaging because it determines the ability to freeze the motion of the beating heart, thus reducing motion artifacts and improving image clarity. Unlimited 1-Beat Cardiac in the Revolution Apex systems delivers 19.5msec effective cardiac temporal resolutionⁱ, enabled by the fastest 0.23s gantry rotation and SnapShot Freeze 2 whole-heart motion-correction algorithm. This hardware-plus-software temporal resolution is crucial for the robustness of Unlimited 1-Beat Cardiac in imaging challenging cardiac patients with increased heart rates to improve image quality and diagnostic accuracy of 1-beat CCTA⁸. For CT systems without this effective temporal resolution, multisegment reconstruction that requires multi-beat cardiac acquisition is often required, which increases the risks of stair-step artifacts and higher radiation dose.


ⁱ Effective temporal resolution achieved by a 6x improvement of motion-blur reduction while maintaining high spatial resolution as demonstrated in cardiac phantom testing. The reduction in motion artifacts is comparable to a 0.039 Equivalent Gantry Rotation Speed with effective temporal resolution of 19.5msec at 0.23sec gantry rotation time, as demonstrated in mechanical and mathematical phantom testing. This is the experience of a single facility and may not be generalizable or reproducible. 19.5ms temporal resolution is available on the Apex Elite and Apex Plus.



160mm z-coverage Clarity Detector
For high-resolution imaging



Up to 1300mA power
For low kV scanning and obese patients



0.23s
The industry's fastest rotation with intelligent motion correction

Auto Gating

Auto Gating is the brain of Unlimited 1-Beat Cardiac acquisition. Based on the real-time monitoring of a patient's ECG signal, Auto Gating can automatically identify and recommend the ideal timing to scan the whole heart in a single beat at any heart rate, and the optimal phase or phase range of one cardiac cycle when motion is minimal (Figure 2). Auto Gating synchronizes a CT system with 16cm whole-heart coverage to enable 1-Beat Cardiac acquisition for any heart rates. The feature also contributes to dose reduction by ensuring that the X-ray exposure is limited to the necessary phase(s) of only one cardiac cycle.

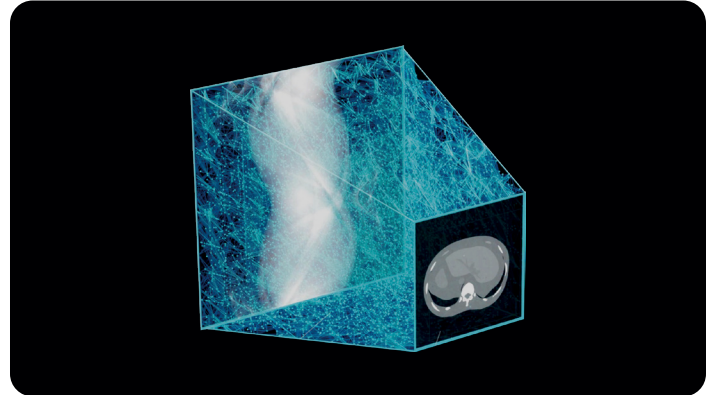
Smart Arrhythmia Management

Smart Arrhythmia Management is designed specifically to enhance the robustness of 1-Beat Cardiac acquisition for challenging patients with arrhythmia. If an arrhythmia is detected, the Smart Arrhythmia Management feature can adjust in real-time the scan timing to capture a normal heart cycle. This capability minimizes the chances of failed cardiac scans, reducing the need for repeat scans, saving time and reducing radiation exposure to patients with no technologist interaction.

Cardiac Smart Phase

Cardiac Smart Phase is a reconstruction feature designed to intelligently select the best cardiac phase for image reconstruction. With Smart Phase, the acquired phase range is automatically searched in 2% phase intervals during the reconstruction process to determine the optimal phase with least coronary motions for image reconstruction. This ensures improved image quality with the least motion and enhances workflow by reducing the need for manual phase adjustments⁹.

TrueFidelity Deep Learning Image Reconstruction



TrueFidelity

Delivers outstanding detail and clarity texture at low dose

A first of its kind, TrueFidelity utilizes a deep neural network-based reconstruction engine, which was trained to differentiate noise from signals and to intelligently suppress the noise without impacting anatomical and pathological structures. TrueFidelity CT images can deliver superior cardiac CT image quality with reduced noise and preferred noise texture for high diagnostic accuracy¹⁰. It also potentially helps to reduce the X-ray radiation dose and iodine contrast medium administered to patients^{6,11,12}.

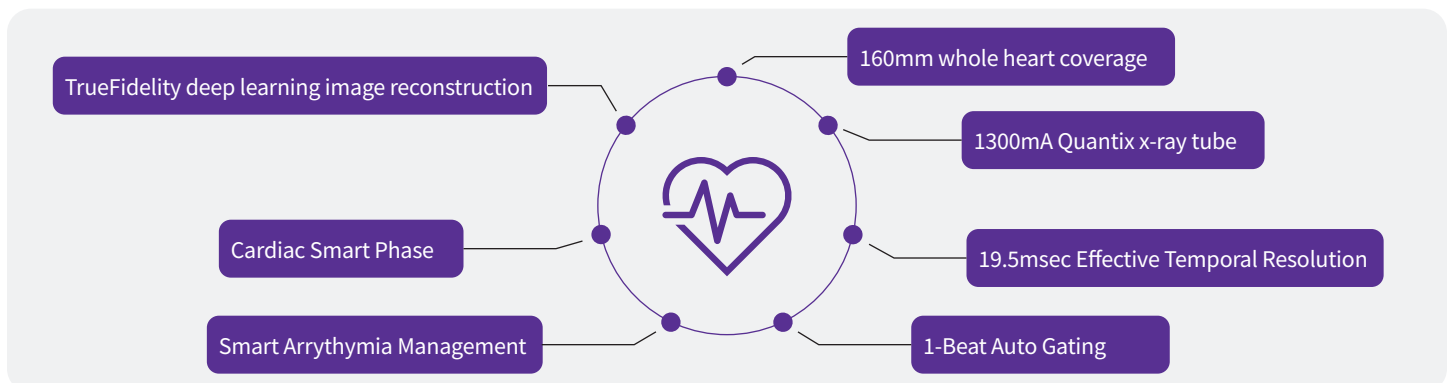


Figure 3. Technology Enablers

Technology enablers of Unlimited 1-Beat Cardiac include wing-to-wing hardware and software innovations in data acquisition and image reconstruction.

Improve CCTA Diagnostic Performance in Patients with Very High Heart Rate (>80bpm)

Diagnostic performance of CCTA can be compromised by motion and stair-step/slice misalignment artifacts due to high HR and heart rate variability (HRV)¹³. High HR (>80bpm) is often observed in patients admitted in the emergency department for acute chest pain and suspected acute coronary syndrome, an emergent situation for which CCTA has a critical clinical role.

To evaluate the diagnostic performance of Unlimited 1-Beat CCTA in patients with high HR, Andreini et al. enrolled 202 patients in a prospective study³. Among the patients admitted for CCTA, 100 had a HR ≥ 80 bpm (mean age: 64 ± 8 years; mean BMI: 27.4 ± 5.2 kg/m²; mean HR: 93.2 ± 23.6 bpm), while the remaining 102 had a HR ≤ 65 bpm (mean age: 68 ± 8 years; mean BMI: 26.4 ± 3.6 kg/m²; mean HR: 57.3 ± 6.8 bpm). The qualitative assessment led by two independent reviewers revealed that the image quality was high in each group without significant difference between the two (score of 3.35 ± 1.3 vs. 3.39 ± 1.3 on a 4-point Likert scale, $p = ns$, in HR ≥ 80 bpm and ≤ 65 bpm groups, respectively), which led to a similarly excellent segment interpretability rate in both groups (97.3% vs. 98% , $p = ns$, in HR ≥ 80 bpm and ≤ 65 bpm groups, respectively). Additionally, on a segment-based analysis, CCTA had a comparable diagnostic accuracy for the detection of >50% stenosis between groups of patients with low and high HR (sensitivity, specificity, and accuracy of 95.2 vs. 95.4 , 98.9 vs. 98.1 and 98.7 vs. 97.7 in HR ≥ 80 bpm and ≤ 65 bpm groups, respectively).

Although previous studies demonstrated that good image quality could be achieved in CCTA of patients with HR ≥ 80 bpm using CT such as like 128-slice dual-source systems, it was at the expense of a relatively high radiation dose (mean effective dose >20 mSv)¹⁴. On the contrary, the results from Andreini et al. showed that the use of the Unlimited 1-Beat Cardiac on Revolution CT allowed clinicians to achieve a markedly lower radiation exposure in high HR patients (2.9 mSv vs. 1.1 mSv in HR ≥ 80 bpm and ≤ 65 bpm groups, respectively) by acquiring data within an acquisition window of 500ms (corresponding to the phase between end-systole and end-diastole). (Figure 4)

Publication Conclusion

Unlimited 1-Beat Cardiac allows high CCTA diagnostic accuracy for the detection of >50% coronary stenosis, with markedly low radiation exposure in high heart rate patients (2.9 mSv in heart rate ≥ 80 bpm) by acquiring data within the phase between end-systole and end-diastole in one cardiac cycle³.

High Heart Rate

Acquisition

Scan type	1-Beat Axial Gated
Rotation time, s	0.23
BPM	139
Slice, mm	0.625
Reconstruction	DLIR
Auto prescription	80kV
mA	1300
Contrast	
ml - mg/ml	28 - 370
Reconstruction	Standard
CTDIvol, mGy	7.8
DLP, mGy-cm	125
Eff. dose, mSv	1.7
k, *DLP	0.014
BMI	26.3

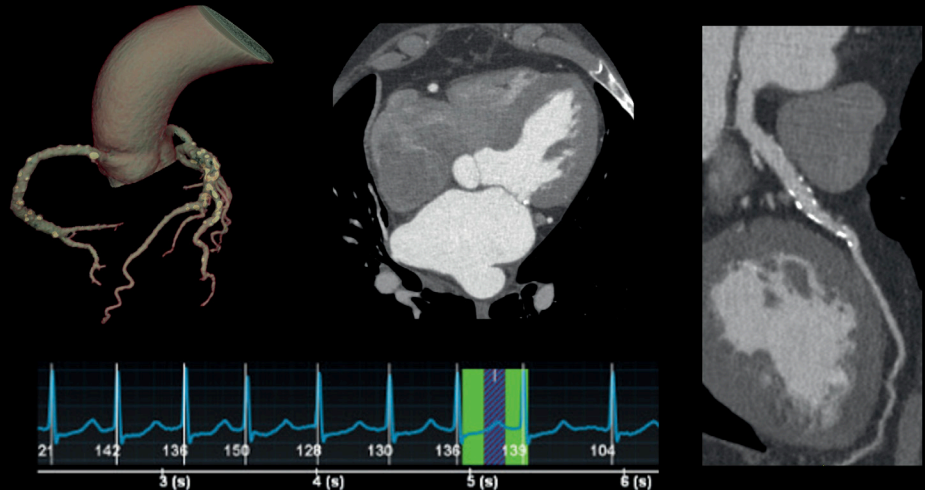


Figure 4. Unlimited 1-Beat CCTA with exceptional low radiation dose and iodine contrast volume for a patient with high HR and HR variability. An 80kV/1300mA/0.23s 1-Beat acquisition (green box) was performed when heart rate was 139bpm. Smart Phase selected the optimal phase (blue box) to reconstruct with TrueFidelity deep-learning image reconstruction. Unlimited 1-Beat Cardiac delivered motion-free and stair-step-free CCTA images with high diagnostic quality, low radiation dose (1.7mSv) and low iodine contrast volume (28ml).

Images courtesy of Prof. Kaufmann, University Hospital Zürich, Switzerland

Improve CCTA Diagnostic Performance in Patients with Atrial Fibrillation

AF is a common type of arrhythmia that's increasing prevalence. It causes the upper chambers of the heart to beat rapidly and irregularly. Patients with AF have been reported to have higher risk of cardiovascular events, including stroke, heart failure and other complications for which a non-invasive evaluation using a cardiac CT provides high clinical value.

AF, however, poses significant challenges to the diagnostic performance of CCTA primarily due to motion and stair-step artifacts caused by high HR and high HRV. For CT without a whole-heart-coverage detector, retrospectively ECG-gated helical acquisition should be considered in AF cases¹³, which results in higher radiation doses and longer post-processing time to conduct ECG editing or select the best phase for image reconstruction¹⁵. Previous studies performed in small groups of patients with AF enabled researchers to confirm that image quality, coronary artery interpretability and diagnostic accuracy of CCTA are still suboptimal, particularly when high HR and HRV are present¹⁶⁻²¹.

Unlimited 1-Beat Cardiac provides a robust acquisition and image reconstruction solution to scan the AF cases with low radiation dose and without stair-step artifacts (Figure 5). A great number of prospective studies have evaluated its robustness and diagnostic performance.

Andreini et al. compared the image quality, interpretability, diagnostic accuracy and radiation exposure of CCTA between 83 patients with AF and 83 patients with sinus rhythm (mean HR: 83 ± 21 vs. 63 ± 14 bpm; HRV: 33 ± 24 vs. 5 ± 4 bpm in the AF and sinus rhythm groups, respectively)²². The study highlighted that the image quality in exams of AF patients was excellent and comparable to the quality of exams in patients with sinus rhythm (score of 3.25 ± 1.2 vs. 3.31 ± 1.2 on a 4-point Likert scale, $p = ns$, in AF and sinus rhythm groups, respectively). Accordingly, the overall coronary interpretability was similar in the two groups (98.5 % vs. 98.4 %, $p = ns$, in AF and sinus rhythm groups, respectively). Those image quality and interpretability performances resulted in a high diagnostic accuracy of CCTA in patients with AF, compared to the gold standard of invasive coronary angiography (ICA). Notably, in a subgroup of 22 patients with HR >90 bpm, sensitivity and specificity were 98.4% and 99.6%, respectively, in a segment-based analysis and 92.3% and 87.5%, respectively, in a patient-based analysis.

Some prior studies had already showed good image quality and high diagnostic accuracy in patients with AF, which was achieved only when HR was low¹⁵, or <70 bpm, even when the latest generations of CT systems were used²³. However, it was achievable at the expense of a significantly high effective radiation dose, ranging from 9 to 16 mSv. Conversely, using Unlimited 1-Beat Cardiac acquisition protocol on the Revolution CT allowed Andreini et al. to achieve a good image quality and high diagnostic accuracy in patients with AF at a markedly lower effective dose of 3.9 ± 2.1 mSv.

Concordant findings were reported by Wen et al. in a study evaluating the impact of HR and HRV on the image quality and radiation dose of CCTA in 70 patients with AF²⁴. Two experienced radiologists assessed the image quality (in terms of visibility and artifacts on a 4-grade rating scale from 1: excellent to 4: insufficient) of the exams, which were divided into four groups according to patient's HR or HRV (group A: HR, ≥ 75 bpm, $n = 36$; group B: HR < 75 bpm, $n = 34$; group C: HRV ≥ 50 bpm, $n = 26$; and group D: HRV < 50 bpm, $n = 44$). Despite significant difference in HR between group A and B (111.6 ± 37.2 vs. 63.2 ± 6.7 bpm, respectively) and in HRV between group C and D (66.3 ± 13.0 vs. 17.9 ± 12.9 , respectively), the compared groups had good and similar image quality (1.62 ± 0.39 vs. 1.49 ± 0.38 , $p = .654$, for groups A and B, respectively; 1.59 ± 0.44 vs. 1.53 ± 0.36 , $p = .147$, for groups C and D, respectively) associated with a high global interpretability rate (98.4%). Those results led the authors to conclude that CCTA of patients with AF offered diagnostic value without HR or HRV significantly impacting image quality. Regarding patient exposure, while higher HR or HRV led to increased effective dose, Unlimited 1-Beat Cardiac on the Revolution CT allowed clinicians to keep it relatively low (3.76 ± 2.22 vs. 2.30 ± 2.02 mSv, $p = .05$, for groups A and B, respectively; 3.89 ± 2.35 vs. 2.56 ± 2.03 mSv, $p = .05$, for groups C and D, respectively).

Publication Conclusion

Unlimited 1-Beat Cardiac reaches a high diagnostic accuracy of CCTA in patients with atrial fibrillation, compared to the gold standard of ICA, at a markedly lower effective dose of less than 4 mSv on average²².

Atrial Fibrillation

Acquisition

Scan type	1-Beat Axial Gated
Rotation time, s	0.23
BPM	47-151
BMI	20
Slice, mm	0.625
Reconstruction	DLIR
Auto prescription	100kV
mA	330
Contrast	
ml/flow - mg/ml	40/4.0 – 320
Reconstruction	HD Standard
CTDIvol, mGy	7.88
DLP, mGy-cm	126
Eff. dose, mSv	1.7
k, *DLP	0.014

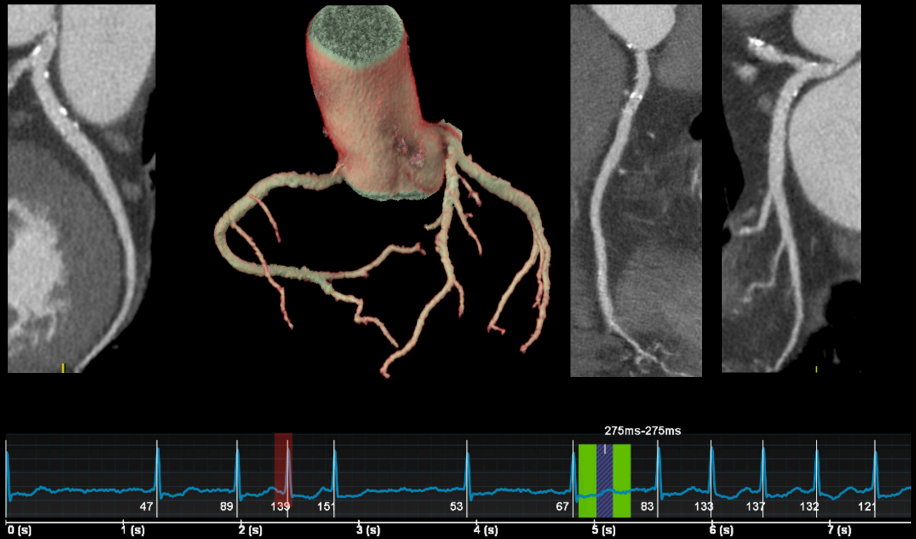


Figure 5. Unlimited 1-Beat CCTA in a patient with atrial fibrillation.

Electrocardiogram shows high HR and HR variability (47-151bpm) during the scan in this patient with AF. Smart Arrhythmia Management feature kicked in and intelligently avoided a premature beat (red box). 1-Beat acquisition was successfully performed when heart rate dropped to 67bpm (green box) and reconstructed 275ms data (blue box) with TrueFidelity. The image quality ensures exceptional coronary artery interpretability. The radiation dose for CCTA was only 1.7mSv.

Images courtesy of Prof. Kaufmann, University Hospital Zürich, Switzerland

Explore Free-Breathing CCTA without Heart Rate Control

CCTA scans usually require an inspiratory breath-holding cooperation of patients to reduce artifact caused by respiration. In practice, some factors may affect a patient's ability to hold their breath, such as elderly patients with reduced lung capacity, patients with chronic obstructive pulmonary disease, asthma, or other respiratory conditions, and patients with anxiety or claustrophobia. For these patients, resultant major stair-step artifacts hamper the sufficient evaluation of the coronary arteries. The feasibility of performing free-breathing CCTA has been reported on 320-detector CT and dual-source CT using high-pitch scanning mode^{25,26}, but is limited to scanning patients with stable and low HR (e.g. < 75bpm or < 60bpm).

To assess the feasibility of free-breathing CCTA without HR control on higher HR using Unlimited 1-Beat Cardiac protocols on Revolution CT, Liu et al. enrolled 616 patients, among which 325 were scanned during breath-holding (mean age: 64.1 ± 10.6 years; mean BMI: 25.2 ± 3.2kg/m²; mean HR: 70.8 ± 13.8bpm) and 291 underwent a free-breathing exam (mean age: 64 ± 8 years; mean BMI: 27.4 ± 5.2kg/m²; mean HR: 93.2 ± 23.6bpm)²⁷. The assessment of the objective (signal to noise ratio of the aorta) and subjective image quality (on a 4-grade rating scale; from 1: excellent to 4: poor) revealed no significant difference between the two groups (SNR: 16.55 ± 4.65 vs. 15.61 ± 3.79, p=.358 ; image quality score: 1.49 ± 0.62 vs.1.53 ± 0.67; p=.647; for breath-holding and free-breathing groups, respectively). Similarly, in a segment-based analysis, the sensitivity, specificity and diagnostic accuracy in the detection of >50% coronary stenosis did not differ between breath-holding and free-breathing acquisitions (82.1 vs. 82.2%, 96.8% vs. 96.6%, and 92.2 vs. 92.2%, p>.9). Finally, holding breath or not during the scan had no significant impact on the radiation dose delivered to the patients (mean effective dose: 1.99 ± 0.83mSv vs. 2.01 ± 0.88mSv, p=.975, for breath-holding and free-breathing groups, respectively).

Publication Conclusion

Unlimited 1-Beat Cardiac enabled free-breathing coronary evaluation with excellent image quality and remarkable diagnostic accuracy despite high heart rate during the acquisition. Image quality, radiation dose and diagnostic accuracy in free-breathing patients were comparable with those with breath-holding²⁷.

Explore CCTA without Heart Rate Control

Traditionally, CCTA acquisition has required the administration of beta-blockers to gain adequate HR control. This has commonly been given on the CT table as an intravenous injection or orally outside the scanner with monitoring; patient appointment times have been 30 minutes or more.

Based on Unlimited 1-Beat CCTA robustness in imaging patients with high HR and arrhythmia, clinicians explored the feasibility of conducting CCTA without HR control.

Morgan-Hughes et al. reported that a radiographer-led Cardiac CT service delivered 20-minute timeslots for CCTA of patients with stable chest pain without administration of beta-blockers or nitroglycerin²⁸. Among the 1024 patients (mean age: 63 ± 13 years; mean BMI: 29 ± 6kg/m²; mean HR: 70±(40-148)bpm) included in this retrospective analysis, according to the reporting cardiologist's or radiologist's ability to provide a definitive Coronary Artery Disease Reporting and Data System (CAD-RADS) score, 96.5% of the exams were considered diagnostic. All CCTA exams were acquired with a median dose-length product (DLP) of 179mGy.cm corresponding to an estimated total effective radiation dose of 4.5mSv.

Publication Conclusion

With Unlimited 1-Beat Cardiac CT and experienced radiographers, drugless (no beta-blocker) radiographer-led CCTA can deliver a 20-minute CCTA timeslot for cardiac patients with satisfactory image quality, while allowing reallocation of medical practitioner time to CCTA reporting²⁸.

¹ The practice of not administering beta-blockers varies by facility and practices may differ at individual facilities. Always respect the drug's prescribing information.

CCTA at Low Dose of Radiation and Contrast Injection

Unlimited 1-Beat Cardiac can potentially optimize radiation dose and the amount of contrast media by reducing total acquisition time and applying low kV protocols with TrueFidelity deep-learning image reconstruction. (Figure 6)

Li et al. explored the use of 70kVp tube voltage combined with the High level of TrueFidelity in reducing both radiation and contrast doses in 1-Beat CCTA in normal size patients in comparison with conventional scan protocol using 120kVp tube voltage and iterative reconstruction⁶. The analysis of 100 exams (50 in low-dose group and 50 in conventional protocol group; mean age: 65±13 vs. 61±11 years, p =.164 ; mean BMI: 22.60±2.06 vs. 22.55±2.36kg/m², p =.908 ; mean heart rate : 74.46±12.42 vs 70.88±14.54bpm, p=.189) reported that the use of 70kVp tube voltage combined with the high level of TrueFidelity for CCTA could reduce radiation dose by 54.5% (0.75±0.14 vs. 1.65±0.66mSv in conventional protocol; p<.0001; and iodine contrast medium usage by 50.6% (3.82±3.69 vs. 48.23±6.38mL) in conventional protocol; p<.0001), while further improving image quality compared with the conventional 120kVp tube voltage with iterative reconstruction.

Similarly, they investigated the use of 80kVp tube voltage combined with a high level of TrueFidelity and reduced contrast dose in comparison with standard acquisition (120kVp with iterative reconstruction) and injection protocols in CCTA of 100 overweight patients (50 in low-dose group and 50 in conventional protocol group; mean age: 63±12 vs. 61±10 years, p =.233; mean BMI: 28.05±1.47 vs. 27.81±1.40kg/m², p =.399; mean heart rate: 71.42±12.48 vs 68.78±13.82bpm, p=.319)⁷. Again, the results showed that the application of 80kVp and TrueFidelity allowed the reduction of radiation dose by up to 45% (1.01±0.45 vs 1.85±0.40mSv in conventional protocol, p <.001) and of contrast dose by up to 43% (33.69±3.87 vs 59.11±5.60mL, p <.001) in comparison to standard protocols, while further improving image quality in CCTA for overweight patients.

Publication Conclusion

Unlimited 1-Beat Cardiac with low kV and TrueFidelity is reported to demonstrate up to 54.5% radiation dose reduction and 50.6% iodine contrast medium usage reduction in normal size patients⁶, with up to 45% radiation dose reduction and 43% iodine contrast medium usage reduction in overweight patients⁷.

Ultra-low dose

Acquisition

Scan type	Axial Gated
Rotation time, s	0.23
BPM	61
BMI	19.6
Slice, mm	0.625
Reconstruction	DLIR
Auto prescription	80kV
mA	350
Contrast	
ml – mgI/ml	25 – 320
Reconstruction	HD Standard
CTDIvol, mGy	1.19
DLP, mGy-cm	19.1
Eff. dose, mSv	0.26
k, *DLP	0.014

0.26mSv, 25ml contrast medium

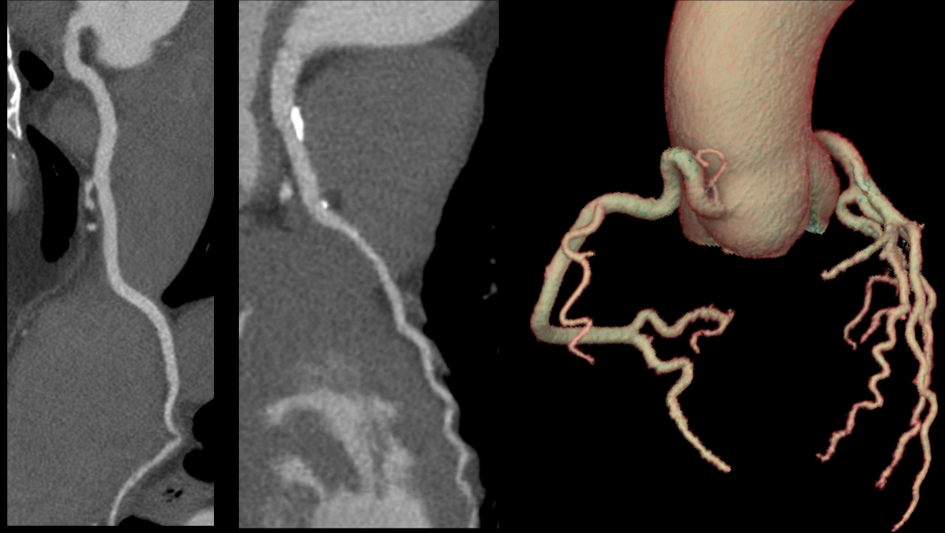


Figure 6. Unlimited 1-Beat Cardiac with 80kV and 0.23s achieves exceptional image quality with ultra-low dose (0.26mSv) and low contrast medium volume (25ml).

Submillisievert CCTA in Children with Coronary Artery Anomalies

Congenital heart disease (CHD) is the most common congenital anomaly, and CT has been established as an effective non-invasive imaging tool to assess complex CHD for over two decades. Coronary artery anomalies are commonly associated with CHD. It is important to evaluate these anomalies to avoid errors in diagnosis and decrease technical difficulties in surgery²⁹. With limitations of echocardiography and cardiac MR in fully characterizing coronary anatomy, especially in evaluating the distal coronary artery for younger CHD patients with coronary artery anomalies, CCTA has superior accuracy for this indication because of its ability to simultaneously visualize the complete coronary arteries and the great vessels.

Performing CCTA in the pediatric population is technically challenging because of elevated HR during acquisition, uncontrolled patient movements and complex anatomies. Conventional prospectively ECG-triggered monophasic acquisitions (without any padding) are often used to minimize the radiation dose, but may lead to 11% to 15% of non-diagnostic or suboptimal quality examinations due to higher and unstable HR. Retrospective ECG-gated acquisitions can achieve high image quality through multiphasic acquisition when HR is high, but often result in a substantial amount of radiation, from 3 to 11mSv³⁰⁻³³.

Unlimited 1-Beat Cardiac on Revolution CT and Revolution Apex provides versatile 1-beat acquisition protocols to adapt the acquisition window within the cardiac cycle as a function of patients' HR and HR variability to achieve better (higher image quality) and safer (lower radiation dose) CCTA (Figure 7).

The COROPEDIA trial (Observational Study for Feasibility and Performance of Sub-millisievert Coronary Computed Tomography Angiography for Coronary Artery Anomalies in Pediatric Patients) was established to prospectively assess the feasibility of this new way of performing submillisievert CCTA on children with CHD.

Fifty pediatric patients (mean age: 6.1 ± 4.9 years; mean HR: 90 ± 26 bpm; mean HRV: 14 ± 11 bpm) with CHD and a suspected or confirmed coronary artery anomaly underwent CCTA performed within a single heartbeat³⁴. A specific CT acquisition scheme, made up of one central phase at the maximum radiation dose and a secondary phase receiving only a fraction of this dose, was designed to acquire projections at the best theoretical phase within the cardiac cycle. While the secondary phase was included between 25% and 85% of the R-R interval, the position of the central phase within the cardiac cycle was determined according to patient HR and HRV (1: a diastolic acquisition for patients with HR below 80bpm; 2: a systolic acquisition for patients with HR above 80bpm; 3: a widened acquisition window for patients with HR higher than 80bpm or HR variability defined as variable or irregular; 4: a shifting acquisition window towards the end of the R-R interval on the ECG with increasing HR), resulting in a total of 15 acquisition scenarios automatically selected based on the patient's ECG.

The image analysis conducted by two independent radiologists – in terms of diagnostic performance, artifacts, noise and artery visualization on a 4-point scale (from 1: non-diagnostic to 4: excellent) – revealed that all CCTAs performed were adequate to fully answer the clinical question using an effective dose inferior to 1mSv (0.97 ± 0.34 mSv). 47 exams presented good or excellent image quality for diagnosis and 3 were scored as adequate; no exam was considered not assessable (mean score of 3.6 for all segments). Very weak to no correlation was found between image quality and mean HR ($r=-0.19$; $P=0.19$) or HRV ($r=-0.16$; $P=0.27$).

Publication Conclusion

For the first time in a pediatric population, the COROPEDIA clinical trial demonstrated the feasibility of using Unlimited 1-Beat CCTA for pediatric patients with coronary artery anomalies, with submillisievert radiation dose³⁴.

6-year-old pediatric patient with left coronary reimplantation at BPM 154

Acquisition

Scan Type	1-Beat Cardiac with 120mm collimation
Gating, %	30 – 80
BPM	154
Rotation time, s	0.28
Slice, mm	0.625
TrueFidelity	High
Kernel	HD Standard
Contrast	
ml – mg/ml	25 - 350
kV	80
CTDIvol, mGy	3.32
DLP, mGy-cm	46.43
Eff. dose mSv	0.84
k, *DLP	0.018

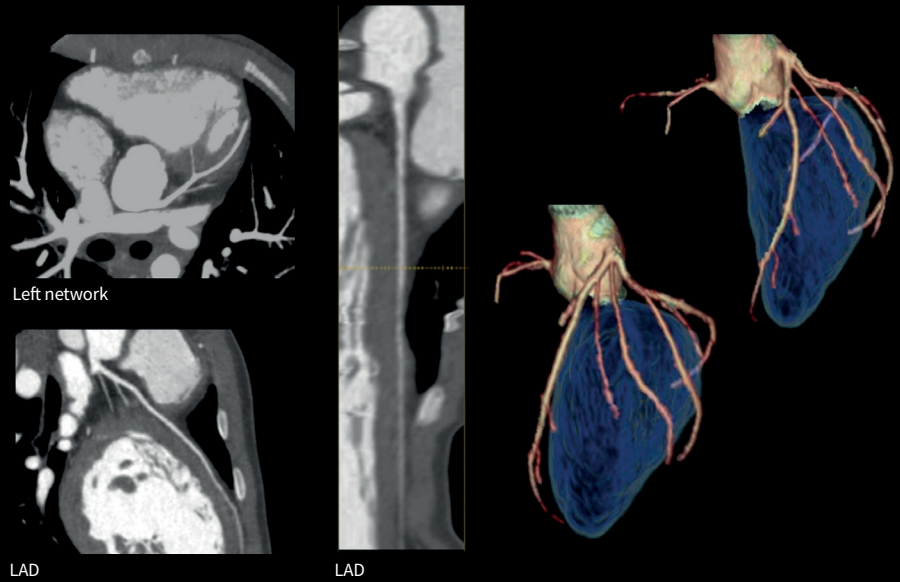


Figure 7. Unlimited 1-Beat Cardiac for post-surgery evaluation of the left coronary reimplantation in a 6-year-old pediatric patient with the left coronary originated from the trunk of the pulmonary arteries.

Images courtesy of Pr Alison, Robert Debré University Hospital, Paris, France

Improve Diagnostic Performance in Patients with Functionally Significant CAD

CCTA has been established as the first-line test to evaluate stable CAD based on its high sensitivity for the identification of significant coronary stenoses and excellent negative predictive value for ruling out obstructive CAD in stable patients with chest pain. It is, however, less robust in specificity and positive predictive value to evaluate functionally significant CAD with intermediate stenoses (30%-90% diameter stenosis)³⁵.

In this regard, CT-derived hemodynamic assessment tools such as CT perfusion (CTP; Figure 8) and CT derived Fractional Flow Reserve (FFRct) have been developed as potential strategies to combine anatomic and functional evaluation in a single scan to improve diagnostic performance of cardiac CT in patients with functionally significant CAD.

Pontone et al. conducted a study using the whole-heart-coverage Revolution CT scanner to investigate the diagnostic performance of stress CTP to detect functionally significant CAD in consecutive intermediate- to high- risk symptomatic patients in comparison to ICA and invasive fractional flow reserve (FFR) as the reference standard³⁶. In 100 consecutive patients (mean age: 66 ± 9 years; mean BMI: $26.8 \pm 4 \text{ kg/m}^2$) scheduled for ICA who underwent rest CCTA (mean HR during acquisition: $62.7 \pm 9 \text{ bpm}$) followed by stress static CTP (mean HR during acquisition: $76.1 \pm 14 \text{ bpm}$); including perfusion imaging significantly improved ($p < .02$ or less) the specificity, the positive predictive value and the accuracy for detecting functionally significant CAD on both per vessel and per patient levels by 18% and 29% (94% with vs. 76% without CTP and 83% with vs. 54% without CTP); 23% and 18% (86% with vs. 63% without CTP and 86% with vs. 68% without CTP) and 10% and 15% (93% with vs. 83% without CTP and 91% with vs. 76% without CTP), respectively.

With the initial evidence, Pontone et al. continued the investigation by conducting a prospective study to compare the diagnostic performance of CCTA+stress CTP, FFRct+CCTA, and CCTA+CTP+FFRct, in consecutive symptomatic CAD patients with intermediate and high-risks³⁷.

85 consecutive symptomatic patients scheduled for ICA (mean age: 64.6 ± 8.2 years; mean BMI: $26.7 \pm 4.5 \text{ kg/m}^2$) prospectively underwent rest CCTA (mean HR during acquisition: $60.2 \pm 8.1 \text{ bpm}$), from which FFRct was measured, followed by stress dynamic CTP (mean HR during acquisition: $86.5 \pm 13.1 \text{ bpm}$). Adding either FFRct or CTP to the CCTA significantly improved the diagnostic accuracy of the CT exam (measured using the area under the ROC curve: 0.876 and 0.878, respectively, vs. 0.826 for CCTA alone; $p < 0.05$). The sequential strategy of CCTA combined with both FFRct and CTP showed the highest area under the ROC curve (0.919; $p < 0.05$).

The main finding of the study is that, while the addition of either FFRct or CTP to a CCTA exam can comparably improve cardiac CT's diagnostic performance to detect functionally significant CAD, CCTA combined with both FFRct and CTP can significantly further improve diagnostic performance, especially for patients with borderline FFRct results between 0.7 and 0.8. The study also found that CTP's radiation dose on whole-heart-coverage Revolution CT in this study was only around 5mSv, approximately 50% less than the dose reported in literature using shuttle mode for dynamic CTP.

Publication Conclusion

A sequential strategy based on Unlimited 1-Beat CCTA followed by FFRct and myocardial perfusion imaging has the ability to provide a full overview of anatomical and functional aspects of CAD³⁶.

Improve Diagnostic Performance in Patients with Suspected In-Stent Restenosis or CAD Progression

Diagnostic performance of CCTA for in-stent restenosis detection is still challenging due to artifacts caused by stent struts. Additionally, the use of FFR_{ct} has not been validated in clinical situations involving the presence of stents and therefore should not be applied in these cases³⁸.

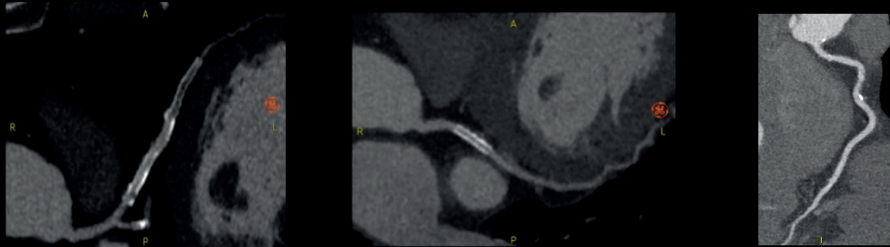
A study conducted by Liu et al. demonstrated that Unlimited 1-Beat Cardiac with TrueFidelity deep-learning image reconstruction in high-resolution scanning mode could maintain a high spatial resolution while reducing metal artifacts and improving the clarity and visibility of the in-stent lumen³⁹. Indeed, the evaluation of 76 stents from 47 patients (mean age: 67±10 years; mean HR: 75±27bpm) revealed that the high level of True Fidelity led to a lower image noise (reduction of 36% and 42% in pre-stent and in-stent image noise compared to ASIR-V 50, respectively), an increased contrast-to-noise ratio (CNR) (71% and 60% in pre-stent and in-stent CNR compared to ASIR-V 50, respectively) an increased signal-to-noise (SNR) (51% and 57% in pre-stent and in-stent SNR compared to ASIR-V 50, respectively). Additionally, according to the two independent radiologists assessing the image quality of the exams, a high level of TrueFidelity reduced metal artifacts by 36% compared to ASIR-V 50 and yielded in-stent diameter measurements closest to the true value associated with sharper stent edges and clearer in-stent lumens.

Andreini et al. conducted the ADVANTAGE trial to investigate the potential value of combined coronary CTA + CTP assessment to additionally increase cardiac CT's diagnostic power in stented patients⁴⁰. 150 stable patients with previous coronary stenting (total number of stents : 470) referred for ICA (mean age: 65.1 ± 9.1 years; mean BMI: 26.6 ± 3.6kg/m²) underwent stress myocardial CTP (mean HR during acquisition: 82 [72.5 - 90]), rest CTP and CCTA (mean HR during acquisition: 60 [55 - 65]). The evaluation of the number of stents interpretable showed that the diagnostic rate of CCTA combined with CTP was significantly higher than the one of CCTA alone at stent (97.6% vs. 88.3%; p < 0.0001), territory (97.3 % vs. 91.1%; p < 0.0001) and patient (97.3% vs. 68.1%; p < 0.0001) levels. In comparison to ICA defined as the gold standard, CTP's diagnostic accuracy was significantly higher than that of CCTA at territory (92.1% vs. 85.5%, p < 0.03) and patient (86.7% vs. 76.7%, p < 0.03) levels. The concordant coronary CCTA with CTP assessment further increased the diagnostic accuracy values in the territory (95.8%) and patient (92.8%) levels. Consequently, the trial demonstrated that in patients with coronary stents and suspected in-stent restenosis or progression of native CAD, CTP significantly improved the diagnostic performance of CCTA while maintaining the total examination at a relatively low radiation dose level (4.15 ± 1.5mSv for CCTA, rest CTP and stress CTP) (Figure 8).

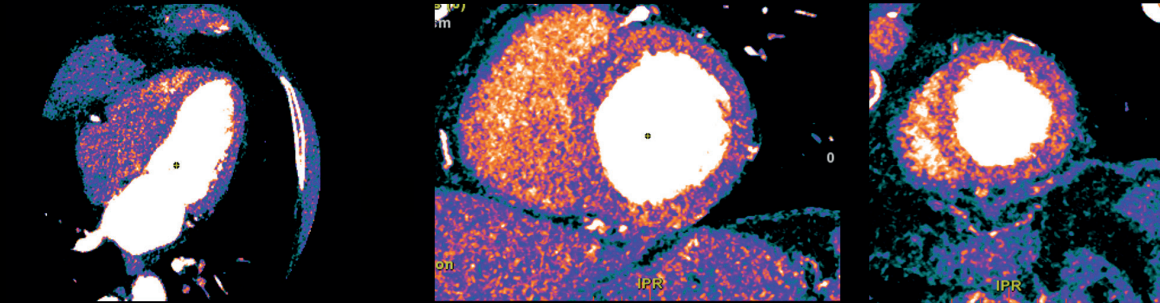
Publication Conclusion

For patients with coronary stents, Unlimited 1-Beat Cardiac with high-resolution mode and TrueFidelity can improve the clarity and visibility of the in-stent lumen³⁹; concordant with CTP can significantly improve overall diagnostic performance while maintaining relatively low radiation dose⁴⁰.

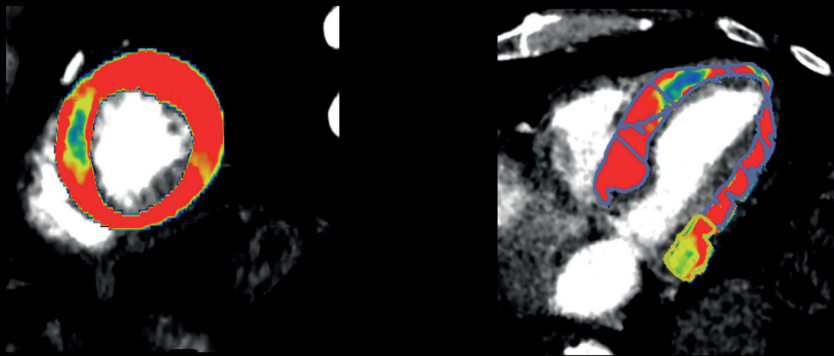
Stented patient with a negative cycle ergometer stress test but a positive CT uncap perfusion



Occlusive intra-stent restenosis (ISR) of LAD stent; Patency of stent on LCX; Mild stenosis on RCA.



No perfusion defect at rest phase.



Dynamic CT perfusion showed pathological values of MBF in mid-apical anteroseptum.

Figure 8. An 80-year-old male with history of hypertension and revascularization with stents in LAD and LCX presented with typical angina. Treadmill test was negative. Unlimited 1-Beat CCTA depicted occlusive intra-stent restenosis of LAD stent. Dynamic CTP showed pathological values of MBF in mid-apical anteroseptum.

Images courtesy of Dr. Mushtaq and Dr. Pontone, Centro Cardiologico Monzino, Milan, Italy.

Replace Invasive Coronary Angiography in Treatment Planning for Patient with Multivessel Disease

Multivessel disease is defined as significant stenosis (>70%) in two or more major coronary arteries of 2.5mm diameter or more. Coronary Artery Bypass Graft (CABG) has been primarily used for revascularization for multivessel disease since 1968. Recent technological and technical advancements in percutaneous coronary intervention (PCI) techniques has broadened the treatment scope to now include patients with multivessel disease. Deciding between CABG and PCI should be made by consensus between cardiologists and cardiac surgeons. ICA has been the gold standard diagnostic method to guide revascularization decision. Nevertheless, one of the major remaining drawbacks of conventional coronary angiography is its invasive nature.

Over the past decade, there has been speculation regarding the possibility of CCTA replacing ICA for the guidance of revascularization procedures. The prospect of sending a patient to surgery based on a purely non-invasive CCTA assessment could potentially decrease medical complications, hospitalization days and costs related to medical treatment.

The SYNTAX III Revolution trial was the first prospective, randomized trial using Unlimited 1-Beat Cardiac to investigate the role of a decision-making process regarding the revascularization strategy based on non-invasive imaging with CCTA in patients with complex multivessel disease⁴¹. Two separate heart teams assessed 223 patients with de novo left main or three-vessel CAD (mean age: 67.6 ± 8.9 years; mean BMI: 26.5 ± 3.7kg/m²; mean HR: 54.6 ± 11.0bpm) based either on CCTA or ICA to provide a treatment recommendation between CABG or PCI guided by SYNTAX score II. The trial concluded that clinical decision-making between CABG and PCI using Unlimited 1-beat CCTA had a high level of agreement with treatment decisions based on ICA (93% concordance and Cohen's kappa 0.82), a finding which prompted the hypothesis that CCTA might provide sufficient, or even superior, information to ICA in planning and performing CABG⁴².

To answer the question of "is it safe and feasible to completely skip ICA before CABG?", the FAST TRACK CABG trial was conducted to assess the feasibility and safety of planning and executing surgical revascularization based solely on 1-Beat Cardiac CCTA and associated FFRct in patients with complex coronary artery disease⁴³. A CCTA heart team reviewed CT images and associated FFRct results from a cohort of 114 patients with chronic coronary syndrome and low surgical risk addressed for CABG (mean age: 65.9 ± 8.7 years; mean BMI: 26.8 ± 4.2kg/m²; mean HR: 67.7 ± 11.9bpm) to define treatment planning and surgical revascularization. The initial ICA was required for only one patient, which resulted in a feasibility rate of 99.1% for CABG guided by CCTA. The trial concluded that the planning and execution of CABG with the sole knowledge of anatomy from CCTA, and without any visual information from conventional ICA, in patients referred for CABG is feasible and deemed safe in a select population with chronic coronary syndrome and low surgical risk.

Publication Conclusion

Unlimited 1-Beat Cardiac might provide sufficient, or even superior, information to ICA in planning and performing CABG^{42,43}.

One-Stop TAVI/TAVR Protocol with Only One Contrast Medium Injection

Transcatheter aortic valve implantation (TAVI)/transcatheter aortic valve replacement (TAVR) procedures, as the treatment strategy for patients with symptomatic severe aortic stenosis, have grown in popularity and scope over the past two decades. TAVI/TAVR was originally only performed on patients at high surgical risk, but these procedures are now also indicated for patients at intermediate risk for conventional surgical valve replacement⁴⁴.

In planning TAVI/TAVR procedures, Cardiac CT has become the gold standard non-invasive imaging tool for peripheral access planning, annular sizing, determination of risk of annular injury and coronary occlusion, and to provide co-planar fluoroscopic angle prediction in advance of the procedure.

Unlimited 1-Beat Cardiac has provided one-stop TAVR/TAVI protocols, allowing mixed acquisitions with only one contrast medium injection: a prospectively ECG-gated 1-beat, whole-heart scan to cover the entire aortic root and heart, including coronary arteries, and non-ECG-gated axial or helical scans to cover the aorto/ilio/femoral vasculature. The protocols enable the holistic assessment of the aortic root, coronary arteries and peripheral vessels in the same exam with low iodine contrast medium use and low radiation dose, potentially leading to a reduction of unnecessary ICA in patients without CAD with a consequent reduction of cumulative iodine contrast medium volumes and the total cost for patient management (Figure 9).

Annoni et al. conducted a study including 115 patients (mean age 82.5 ± 6.2 y, mean BMI 26.7 ± 3.6 kg/m²) referred for TAVI to evaluate feasibility, image quality and diagnostic performance of these protocols⁴⁵. They demonstrated that a low-contrast (50ml of a 400mg/mL agent) scan protocol for CT angiography using Revolution CT with Unlimited 1-Beat Cardiac was safe, feasible and provided accurate information for pre-procedural TAVI planning determining patient eligibility, access strategy and prosthesis selection with very good image quality (median quality score value was >3 on a 4-point visual scale) of both aorta and coronary arteries at an average total effective of about 6mSv. It allowed an overall mean attenuation value >500 HU of aortic segments, peripheral accesses and coronary arteries with high reproducibility of aortic annulus measurements and very good reliability for prosthesis sizing (100% procedural success rate). While high or irregular HR are frequently observed in TAVI candidates because of severe aortic stenosis or AF, the use of Unlimited 1-Beat Cardiac in this study allowed clinicians to perform a scan of the whole heart volume during one heartbeat (0.8 s scan time), reducing the potential artifacts related to HR or movement, even in case of patients with AF (n = 15). It resulted in a segment-based level sensitivity, specificity, negative predictive value, positive predictive value and accuracy for the detection of $>50\%$ stenosis of 97, 85, 99, 62 and 88%, respectively, suggesting that ICA could be avoided in cases of insignificant CAD during pre-TAVI CT examination.

Publication Conclusion

Unlimited 1-Beat Cardiac TAVI protocols allow the holistic assessment of the aortic root, coronary arteries and peripheral vessels in the same exam with low iodine contrast medium use and low radiation dose, potentially leading to a reduction of unnecessary ICA in patients without CAD and the total cost for patient management⁴⁵.

TAVI & CCTA

Acquisition

Scan type	Axial Gated Helical
Rotation time, s	0.28
Pitch	0.992
Slice, mm	0.625mm
Reconstruction	TrueFidelity
kV	100 (CCTA) 120 (non-gated helical)
mA	1088 (CCTA) mA modulation for non-gated helical
Contrast	
ml	65ml
mg/ml	350mg/ml
DLP, mGy-cm	528
Eff. Dose, mSv	7.39

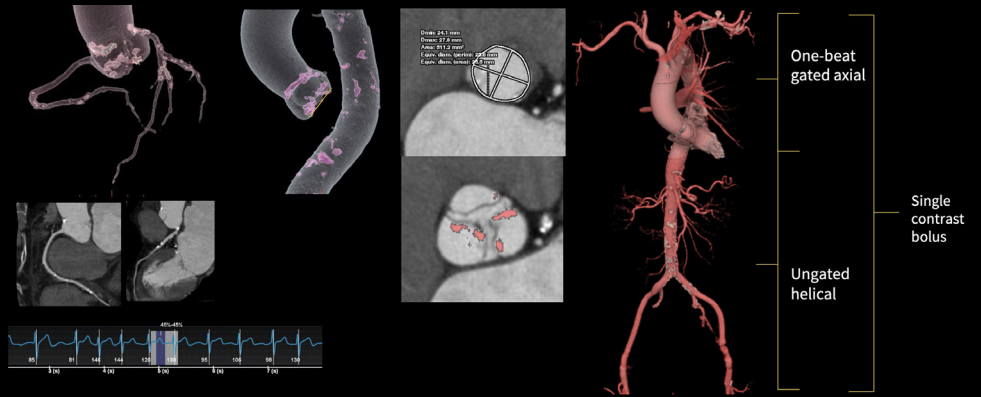


Figure 9. One-stop CT exam for TAVI planning with only one contrast medium injection in a patient with aortic stenosis. Electrocardiogram shows 1-Beat gated acquisition when patient HR was at 120bpm to cover the entire aortic root and heart, including coronary arteries. Followed by ungated helical scan to cover the aorta/ilio/femoral vasculature. Complete exam was performed in a single contrast bolus, which was only 65ml.

Images courtesy of Derriford Hospital – Plymouth Hospitals NHS Trust

Unleash the Full Potential with ECG-less Cardiac

Unlimited 1-Beat Cardiac has been proven to elevate cardiac CT's diagnostic performance for patients with a wide range of clinical scenarios. Can we extend the benefits to patients with more challenging situations where cardiac CT is heavily needed but ECG tracing is not available?

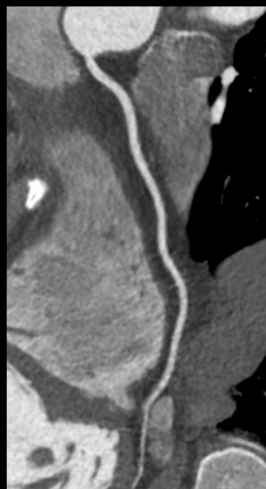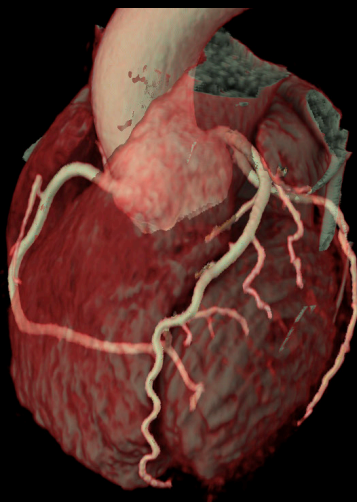
The answer is yes with ECG-less Cardiac, a breakthrough new cardiac CT solution that unleashes the full potential of Unlimited 1-Beat Cardiac.

ECG-less Cardiac uses a simulated R-peak based on the manually entered, estimated patient's HR, which is used to trigger the 1-Beat Cardiac scan to acquire data with a duration determined by the desired phase range of the heart. When a full heart cycle of image data is required, the start of the scan can be determined by contrast timing only, like other CTA exams. The duration of the scan is determined by the period of the patient's average estimated HR, measured prior to the scan.

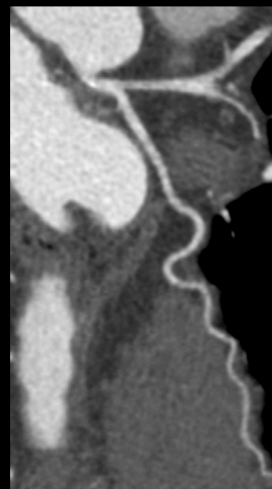
ECG-less Cardiac is applied in examinations where it is clinically advantageous to prioritize patient access or speed when the ECG signal is unavailable (Figure 10). Also, it is designed to address workflow challenges associated with patient prep – including skin prep, attaching ECG patches and grounding strap, ECG impedance check and ensuring the ECG trace is displayed on the operator console – that adds to the overall cardiac exam time.

Clinical image

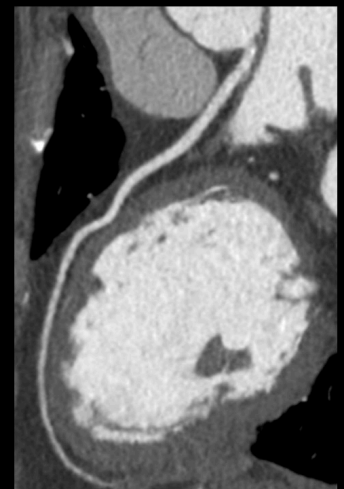
ECG-less Cardiac for acute chest pain patient



RCA



LCX



LAD

Figure 10. ECG-less Cardiac allows exceptional CCTA without ECG trace in a patient with acute chest pain.

References

1. Knuuti, J. *et al.* 2019 ESC Guidelines for the diagnosis and management of chronic coronary syndromes. *Eur Heart J* **41**, 407–477 (2020).
2. Gulati, M. *et al.* 2021 AHA/ACC/AASE/CHEST/SAEM/SCCT/SCMR Guideline for the Evaluation and Diagnosis of Chest Pain: Executive Summary: A Report of the American College of Cardiology/American Heart Association Joint Committee on Clinical Practice Guidelines. *Circulation* **144**, e368–e454 (2021).
3. Andreini, D. *et al.* Diagnostic performance of coronary CT angiography carried out with a novel whole-heart coverage high-definition CT scanner in patients with high heart rate. *Int J Cardiol* **257**, 325–331 (2018).
4. Paul, J.-F., Amato, A. & Rohnean, A. Low-dose coronary-CT angiography using step and shoot at any heart rate: comparison of image quality at systole for high heart rate and diastole for low heart rate with a 128-slice dual-source machine. *Int J Cardiovasc Imaging* **29**, 651–657 (2013).
5. Pontone, G. *et al.* Impact of an intra-cycle motion correction algorithm on overall evaluability and diagnostic accuracy of computed tomography coronary angiography. *Eur Radiol* **26**, 147–156 (2016).
6. Li, W. *et al.* High-strength deep learning image reconstruction in coronary CT angiography at 70-kVp tube voltage significantly improves image quality and reduces both radiation and contrast doses. *Eur Radiol* **32**, 2912–2920 (2022).
7. Li, W. *et al.* Reducing both radiation and contrast doses for overweight patients in coronary CT angiography with 80-kVp and deep learning image reconstruction. *Eur J Radiol* **161**, 110736 (2023).
8. Liang, J. *et al.* Second-generation motion correction algorithm improves diagnostic accuracy of single-beat coronary CT angiography in patients with increased heart rate. *Eur Radiol* **29**, 4215–4227 (2019).
9. Wang, H. *et al.* Clinical evaluation of new automatic coronary-specific best cardiac phase selection algorithm for single-beat coronary CT angiography. *PLoS One* **12**, e0172686 (2017).
10. Benz, D. C. *et al.* Validation of deep-learning image reconstruction for coronary computed tomography angiography: Impact on noise, image quality and diagnostic accuracy. *J Cardiovasc Comput Tomogr* **14**, 444–451 (2020).
11. Benz, D. C. *et al.* Radiation dose reduction with deep-learning image reconstruction for coronary computed tomography angiography. *Eur Radiol* **32**, 2620–2628 (2022).
12. Sun, J. *et al.* Performance evaluation of using shorter contrast injection and 70kVp with deep learning image reconstruction for reduced contrast medium dose and radiation dose in coronary CT angiography for children: a pilot study. *Quant Imaging Med Surg* **11**, 4162–4171 (2021).
13. Abbara, S. *et al.* SCCT guidelines for the performance and acquisition of coronary computed tomographic angiography: A report of the society of Cardiovascular Computed Tomography Guidelines Committee: Endorsed by the North American Society for Cardiovascular Imaging (NASCI). *J Cardiovasc Comput Tomogr* **10**, 435–449 (2016).
14. Matsubara, K. *et al.* 128-slice dual-source CT coronary angiography with prospectively electrocardiography-triggered high-pitch spiral mode: radiation dose, image quality, and diagnostic acceptability. *Acta Radiol* **57**, 25–32 (2016).
15. Vorre, M. M. & Abdulla, J. Diagnostic accuracy and radiation dose of CT coronary angiography in atrial fibrillation: systematic review and meta-analysis. *Radiology* **267**, 376–386 (2013).
16. Oncel, D., Oncel, G. & Tastan, A. Effectiveness of dual-source CT coronary angiography for the evaluation of coronary artery disease in patients with atrial fibrillation: initial experience. *Radiology* **245**, 703–711 (2007).
17. Yang, L. *et al.* 64-MDCT coronary angiography of patients with atrial fibrillation: influence of heart rate on image quality and efficacy in evaluation of coronary artery disease. *AJR Am J Roentgenol* **193**, 795–801 (2009).
18. Rist, C. *et al.* Noninvasive coronary angiography using dual-source computed tomography in patients with atrial fibrillation. *Invest Radiol* **44**, 159–167 (2009).
19. Marwan, M. *et al.* Accuracy of dual-source CT to identify significant coronary artery disease in patients with uncontrolled hypertension presenting with chest pain: comparison with coronary angiography. *Int J Cardiovasc Imaging* **28**, 1173–1180 (2012).
20. Zhang, J.-J. *et al.* Diagnostic Value of 64-Slice Dual-Source CT Coronary Angiography in Patients with Atrial Fibrillation: Comparison with Invasive Coronary Angiography. *Korean J Radiol* **12**, 416–423 (2011).
21. Xu, L. *et al.* Diagnostic performance of 320-detector CT coronary angiography in patients with atrial fibrillation: preliminary results. *Eur Radiol* **21**, 936–943 (2011).
22. Andreini, D. *et al.* Atrial Fibrillation: Diagnostic Accuracy of Coronary CT Angiography Performed with a Whole-Heart 230- μ m Spatial Resolution CT Scanner. *Radiology* **284**, 676–684 (2017).
23. Di Cesare, E. *et al.* Image quality and radiation dose of single heartbeat 640-slice coronary CT angiography: a comparison between patients with chronic atrial fibrillation and subjects in normal sinus rhythm by propensity analysis. *Eur J Radiol* **84**, 631–636 (2015).
24. Wen, B., Xu, L., Liang, J., Fan, Z. & Sun, Z. A Preliminary Study of Computed Tomography Coronary Angiography Within a Single Cardiac Cycle in Patients With Atrial Fibrillation Using 256-Row Detector Computed Tomography. *J Comput Assist Tomogr* **42**, 277–281 (2018).
25. Kang, E.-J. *et al.* An initial randomised study assessing free-breathing CCTA using 320-detector CT. *Eur Radiol* **23**, 1199–1209 (2013).
26. Bischoff, B., Meinel, F. G., Del Prete, A., Reiser, M. F. & Becker, H.-C. High-pitch coronary CT angiography in dual-source CT during free breathing vs. breath holding in patients with low heart rates. *Eur J Radiol* **82**, 2217–2221 (2013).
27. Liu, Z. *et al.* Diagnostic performance of free-breathing coronary computed tomography angiography without heart rate control using 16-cm z-coverage CT with motion-correction algorithm. *J Cardiovasc Comput Tomogr* **13**, 113–117 (2019).
28. Morgan-Hughes, G. *et al.* Drugless and radiographer led: the start of a new era for CT coronary angiography. *Open Heart* **10**, e002263 (2023).
29. Tuzcu, E. M., Moodie, D. S., Chambers, J. L., Keyser, P. & Hobbs, R. E. Congenital heart diseases associated with coronary artery anomalies. *Cleve Clin J Med* **57**, 147–152 (1990).
30. Ghoshhajra, B. B. *et al.* Radiation dose reduction in pediatric cardiac computed tomography: experience from a tertiary medical center. *Pediatr Cardiol* **35**, 171–179 (2014).
31. Tsai, I.-C. *et al.* Visualization of neonatal coronary arteries on multidetector row CT: ECG-gated versus non-ECG-gated technique. *Pediatr Radiol* **37**, 818–825 (2007).
32. Habib Geryes, B. *et al.* Radiation dose reduction in paediatric coronary computed tomography: assessment of effective dose and image quality. *Eur Radiol* **26**, 2030–2038 (2016).
33. Podberesky, D. J. *et al.* Radiation dose estimation for prospective and retrospective ECG-gated cardiac CT angiography in infants and small children using a 320-MDCT volume scanner. *AJR Am J Roentgenol* **199**, 1129–1135 (2012).
34. Le Roy, J. *et al.* Submillisievert Multiphasic Coronary Computed Tomography Angiography for Pediatric Patients With Congenital Heart Diseases. *Circulation: Cardiovascular Imaging* **12**, e008348 (2019).
35. Narula, J. *et al.* SCCT 2021 Expert Consensus Document on Coronary Computed Tomographic Angiography: A Report of the Society of Cardiovascular Computed Tomography. *J Cardiovasc Comput Tomogr* **15**, 192–217 (2021).
36. Pontone, G. *et al.* Incremental Diagnostic Value of Stress Computed Tomography Myocardial Perfusion With Whole-Heart Coverage CT Scanner in Intermediate- to High-Risk Symptomatic Patients Suspected of Coronary Artery Disease. *JACC Cardiovasc Imaging* **12**, 338–349 (2019).
37. Pontone, G. *et al.* Dynamic Stress Computed Tomography Perfusion With a Whole-Heart Coverage Scanner in Addition to Coronary Computed Tomography Angiography and Fractional Flow Reserve Computed Tomography Derived. *JACC Cardiovasc Imaging* **12**, 2460–2471 (2019).
38. Rajiah, P., Cummings, K. W., Williamson, E. & Young, P. M. CT Fractional Flow Reserve: A Practical Guide to Application, Interpretation, and Problem Solving. *RadioGraphics* **42**, 340–358 (2022).
39. Liu, M. *et al.* Effect of deep learning image reconstruction with high-definition standard scan mode on image quality of coronary stents and arteries. *Quant Imaging Med Surg* **14**, 1616–1635 (2024).
40. Andreini, D. *et al.* CT Perfusion Versus Coronary CT Angiography in Patients With Suspected In-Stent Restenosis or CAD Progression. *JACC Cardiovasc Imaging* **13**, 732–742 (2020).
41. Cavalcante, R. *et al.* Non-invasive Heart Team assessment of multivessel coronary disease with coronary computed tomography angiography based on SYNTAX score II treatment recommendations: design and rationale of the randomised SYNTAX III Revolution trial. *EuroIntervention* **12**, 2001–2008 (2017).
42. Collet, C. *et al.* Coronary computed tomography angiography for heart team decision-making in multivessel coronary artery disease. *Eur Heart J* **39**, 3689–3698 (2018).
43. Serruys, P. W. *et al.* Coronary bypass surgery guided by computed tomography in a low-risk population. *European Heart Journal ehae199* (2024) doi:10.1093/eurheartj/ehae199.
44. Reardon, M. J. *et al.* Surgical or Transcatheter Aortic-Valve Replacement in Intermediate-Risk Patients. *N Engl J Med* **376**, 1321–1331 (2017).
45. Annoni, A. D. *et al.* CT angiography prior to TAVI procedure using third-generation scanner with wide volume coverage: feasibility, renal safety and diagnostic accuracy for coronary tree. *Br J Radiol* **91**, 20180196 (2018).

GE Healthcare reserves the right to make changes in specifications and features shown herein, or discontinue the product described at any time without notice or obligation. Contact your GE Healthcare representative for the most current information. GE and the GE Monogram, are trademarks of General Electric Company. GE Healthcare, a division of General Electric Company. GE Medical Systems, Inc., doing business as GE Healthcare.



GE HealthCare