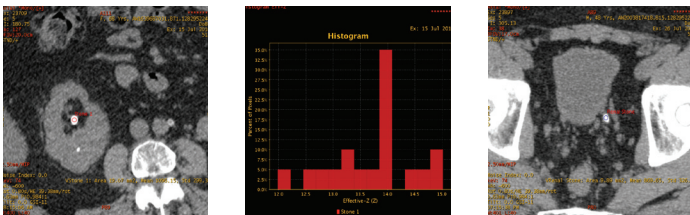


# Gemstone Spectral Imaging helps in characterizing kidney stones.

CT clinical case study—kidney stone quantification



David A. Dowe, MD  
Medical Director, Radiologist  
Atlantic Medical Imaging  
Galloway, NJ



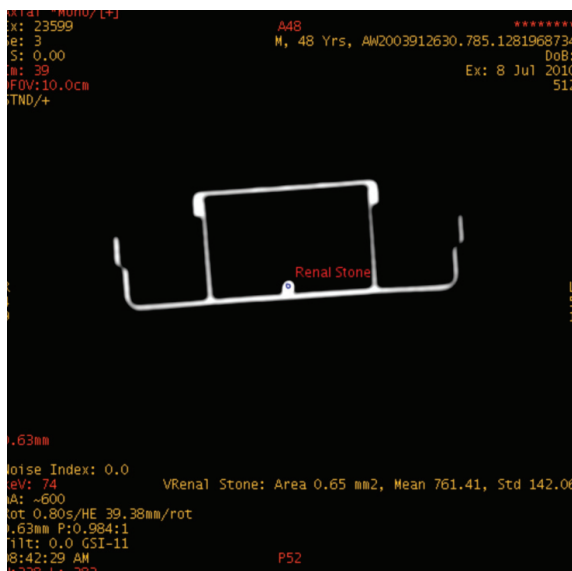

Figure 1. Patient 1 – 74 keV axial view renal calculi

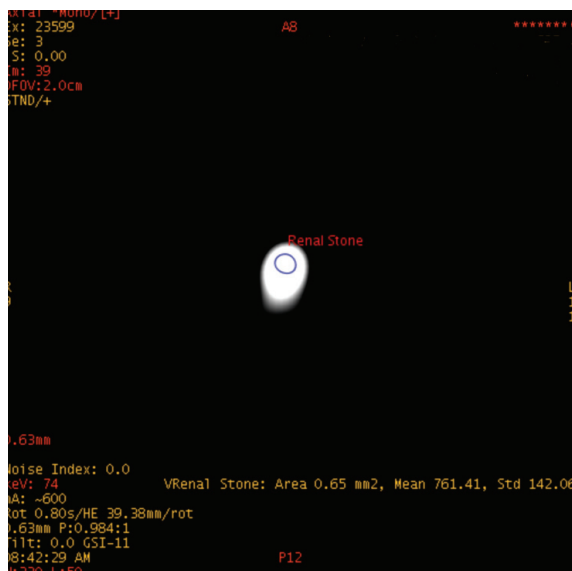


Figure 2. Patient 1 – 74 keV axial view renal calculi ROI

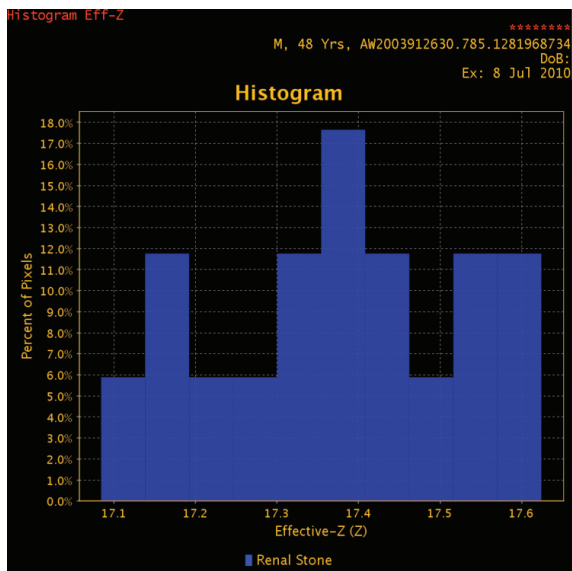


Figure 3. Patient 1 – Effective-Z Plot ROI indicating 17.3 – 17.6 mean atomic number

Kidney stone treatment options vary depending on the composition of the stone, which is identifiable using GSI.

# Case study

---

Realizing kidney stones' quantitative differentiation helps physicians understand their makeup and order a corresponding procedure.

## Abstract

Computed tomography (CT) has long been an invaluable tool in kidney stone diagnosis. However, conventional CT scans have their inherent limits. While it's relatively easy with conventional CT to distinguish among uric acid and non-uric acid stones, it is harder to distinguish different types of non-uric acid stones. Accurately identifying the composition of non-uric acid stones, for example struvite vs. cystine/brushite or calcium oxalate monohydrate, may lead to different treatment of the patient such as deciding whether or not to perform invasive treatments (e.g., ureteroscopic or percutaneous stone removal or laser ablation for fragmentation).

By utilizing Gemstone\* Spectral Imaging—available with the Discovery\* CT750 HD—quantitative differentiation of kidney stones going beyond uric acid vs. non-uric acid stones is possible using effective atomic numbers. With a more exact determination of kidney stone composition, a best course of action is easier to find and a best-case scenario is easier to achieve.

## Patient history

Three patients with histories of renal calculi: Patient One is a 48-year-old male, Patient Two is a 68-year-old female, and Patient Three is a 48-year-old male.


## Exam protocol

GSI acquisition

GSI Viewer Effective-Z Plot for analysis to determine renal calculi composition

## Acquisition protocol

Scanner:	Discovery CT750 HD
Scan type:	GSI—Helical
Detector configuration:	64 x 0.625
Slice thickness:	0.625 mm
Pitch:	0.98:1
GSI preset:	GSI-11
Rotation speed:	0.8 seconds
kVp: Low/High	(80/140 kVp)
SFOV:	50 cm



Determining the makeup of a kidney stone provides valuable treatment direction.

## Discussion and results


In an unusual scenario, Patient One passed and preserved the kidney stone on his own. This provided the opportunity to have the stone scanned using GSI and also sent for lab analysis. Using the Effective Atomic number analysis from the GSI data the stone's Z value measured to be 17.3-17.6 indicating a composition of calcium oxalate monohydrate. The lab result analysis confirmed this finding.

Patient Two received a GSI non-contrast computed tomography of the abdomen and pelvis to reveal a total of four non-obstructive calculi in the right kidney. All four renal calculi had chemical compositions of calcium oxalate monohydrate, calcium oxalate dehydrate, and brushite.

Patient Three received a GSI non-contrast computed tomography of the abdomen and pelvis to reveal a 5mm x 6mm calculi in the left ureterovesical junction (UVJ). The UVJ calculi chemical composition was predominately calcium oxalate dihydrate and cystine.

## Conclusion

Because determining the chemical composition of renal calculi can help a urologist select a strategic course of action—sometimes even before the doctor meets the patient—Gemstone Spectral Imaging Viewer's Effective-Z Image Type and Histogram feature can be used to find the best available treatment based on stone composition. Through use of effective atomic numbers, GSI allows the physician to quantify kidney stone chemical composition and make use of these data in ways conventional CT cannot.



Gemstone Spectral Imaging Viewer's Effective-Z Image Type can help doctors make a confident diagnosis.

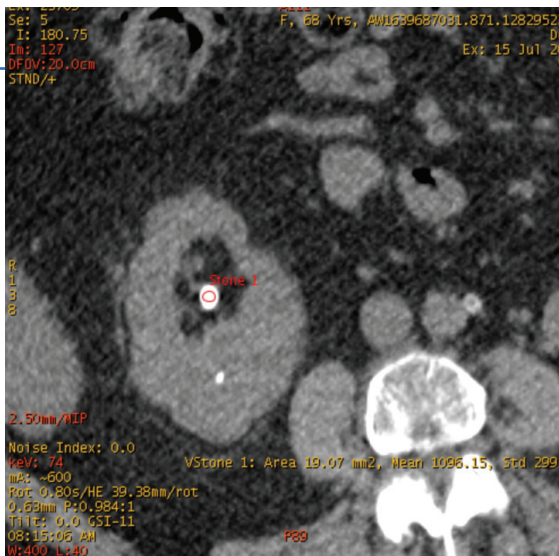


Figure 4. Patient 2 – 74 keV renal calculi 1 axial with ROI

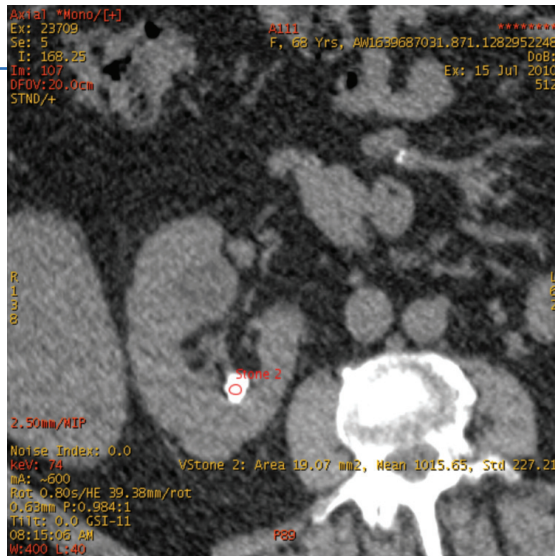


Figure 5. Patient 2 – 74 keV renal calculi 2 axial with ROI

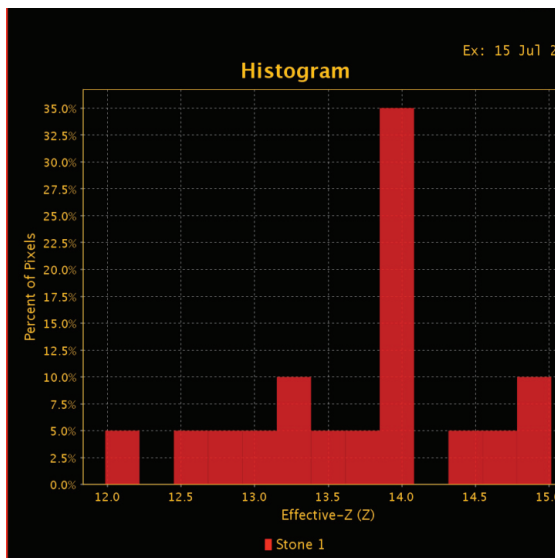


Figure 6. Patient 2 – Renal calculi 1ROI Effective-Z Plot

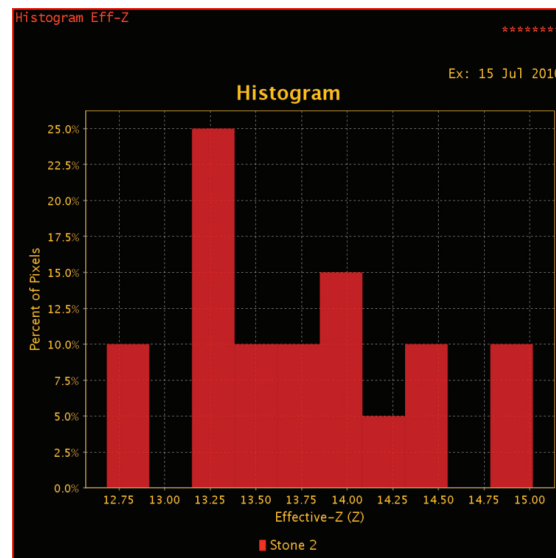


Figure 7. Patient 2 – Renal calculi 2ROI Effective-Z Plot

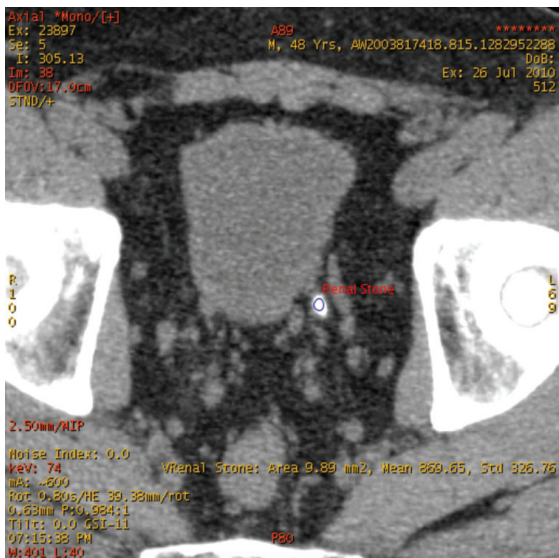


Figure 8. Patient 3 – UVJ calculi ROI

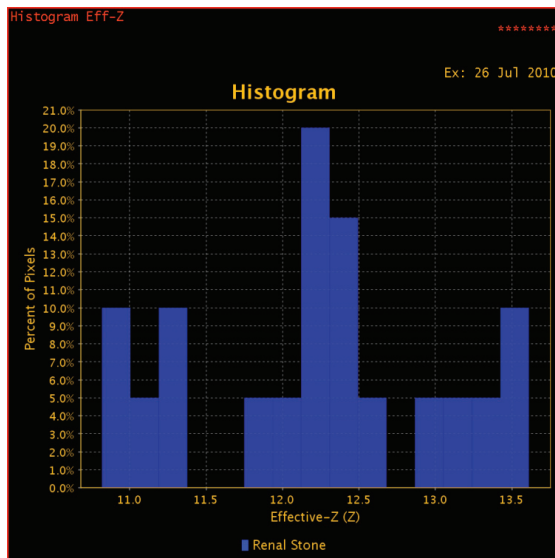


Figure 9. Patient 3 – Renal calculi ROI Effective-Z Plot

©2010 General Electric Company – All rights reserved.

General Electric Company reserves the right to make changes in specifications and features shown herein, or discontinue the product described at any time without notice or obligation.

GE, GE Monogram, Discovery, and Gemstone are trademarks of General Electric Company.

GE Healthcare, a division of General Electric Company.

## About GE Healthcare

GE Healthcare provides transformational medical technologies and services that are shaping a new age of patient care. Our broad expertise in medical imaging and information technologies, medical diagnostics, patient monitoring systems, drug discovery, biopharmaceutical manufacturing technologies, performance improvement and performance solutions services helps our customers to deliver better care to more people around the world at a lower cost. In addition, we partner with healthcare leaders, striving to leverage the global policy change necessary to implement a successful shift to sustainable healthcare systems.

Our “healthymagination” vision for the future invites the world to join us on our journey as we continuously develop innovations focused on reducing costs, increasing access, and improving quality around the world. Headquartered in the United Kingdom, GE Healthcare is a unit of General Electric Company (NYSE: GE). Worldwide, GE Healthcare employees are committed to serving healthcare professionals and their patients in more than 100 countries. For more information about GE Healthcare, visit our website at [www.gehealthcare.com](http://www.gehealthcare.com)

GE Healthcare  
3000 N. Grandview Blvd.  
Waukesha, WI 53188  
U.S.A.



imagination at work